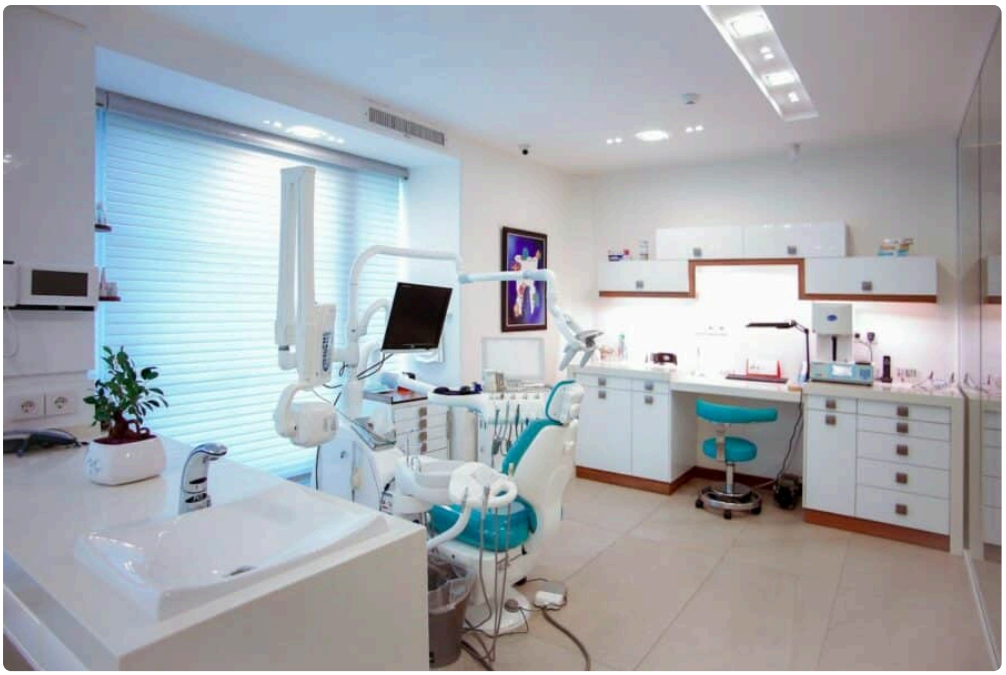

A broken veneer rarely happens at a convenient time. It tends to happen during dinner, before a meeting, on a weekend trip, or late at night when every rough edge feels twice as sharp. The same goes for crowns that come loose, fillings that fall out, and bridges that suddenly shift. Patients often walk in worried about pain, appearance, cost, or the fear that they have done permanent damage. Most of the time, there is a practical path forward, but the first few hours matter more than people think.

Emergency dentist visits for damaged dental work are not only about cosmetics. A chipped porcelain veneer can expose vulnerable tooth structure. A lost crown can leave a prepared tooth sensitive and weak. A cracked filling can trap bacteria and food, turning a repair into decay or inflammation if it sits too long. The urgency depends on what is broken, where it is located, and whether the tooth underneath is healthy. That is why good emergency care starts with calm triage, not panic.

In practice, the goal is simple: protect the tooth, control discomfort, prevent the situation from worsening, and choose the most conservative repair that will hold up. Sometimes that means bonding a small chip. Sometimes it means recementing a crown the same day. Sometimes the emergency appointment is less about fixing everything immediately and more about stabilizing the tooth until a permanent solution can be completed safely.

When broken dental work becomes an emergency

Not every damaged restoration needs after-hours treatment, but some situations should move to the top of your list. Pain is one clue, though not the only one. A front veneer that has broken in half may not hurt much, yet it can leave a sharp edge or exposed dentin that dries out, stains easily, and becomes increasingly sensitive. A molar crown that falls off may seem manageable for a day or two, but the tooth underneath can shift surprisingly fast, making it harder for the crown to fit back properly.

The cases that worry dentists most are the ones with a combination of damage and biological risk. If the broken piece has left the tooth exposed, if there is swelling, bleeding around the gum that does not settle, pain on biting, or temperature sensitivity that lingers, the issue is no longer just mechanical. It may involve the pulp, the ligament around the root, or a crack that extends deeper than the visible damage suggests.

Patients are often surprised that a small-looking problem can hide a larger one. A veneer that pops off cleanly may simply need to be re-bonded if the underlying tooth and veneer are intact. But a veneer that breaks during removal of sticky food sometimes reveals decay at the margin, or a fracture in the natural tooth that was masked until the veneer failed. That is why a proper emergency assessment usually includes more than a quick glance. It may involve radiographs, a bite check, magnification, and careful evaluation of the restoration margins.

Veneers fail in different ways, and the treatment depends on the type of failure

Porcelain veneers are strong when they are well planned, bonded correctly, and used within their limits. They are not indestructible. In day-to-day dentistry, veneer emergencies usually fall into a few categories: a small chip, a larger fracture, complete debonding, or failure of the tooth underneath.

A minor chip near the incisal edge can sometimes be smoothed if the surface is not too sharp and the appearance is acceptable. If the chip is visible when smiling, a dentist may repair it with composite resin. This can work well in the short term, though it has limits. Composite does not wear, reflect light, or resist staining in exactly the same way porcelain does. For a patient who wants the best esthetic match, replacement is often the better long-term choice.

A full fracture through the veneer is more straightforward, though not necessarily easier. If the veneer breaks into multiple pieces, it usually needs replacement. The key question becomes whether the natural tooth beneath is intact. If the tooth is sound and there is enough enamel left for bonding, a new veneer may be possible. If the tooth structure is compromised, the plan may shift toward a crown instead. This is one of those judgment calls that depends on how much tooth remains, where the fracture line sits, and how the patient bites.

Debonded veneers are a different story. If the veneer comes off in one piece and the fit is still precise, recementation may be possible. Success depends on timing and condition. If the veneer has been kept safe, not chipped, and not contaminated repeatedly with household glue or improvised adhesives, the odds improve. If it has dried out, fractured, or been altered, replacement becomes more likely.

Crowns, fillings, bonding, and bridges each create their own kind of emergency

The phrase "dental work" covers a lot of ground, and treatment varies more than many patients expect. A loose crown is often manageable if the crown itself is intact and the tooth underneath is stable. Sometimes the cement has simply failed. Sometimes recurrent decay has undermined retention. An emergency dentist has to check both. Recementing a crown without addressing hidden decay may buy a few weeks and create a bigger problem later.

Lost fillings are common and often underestimated. The open space left behind can be tiny or large, shallow or close to the nerve. A small lost filling on a tooth with no symptoms may be repaired with a fresh filling at the emergency visit. A large lost filling on a heavily restored molar often signals fatigue in the remaining tooth walls. In that case, placing another filling may not be the most durable choice, and a crown or onlay may be discussed.

Dental bonding, especially on emergency dental service front teeth, breaks more often than porcelain because it is more prone to wear and chipping. The upside is that it is usually the easiest to repair quickly. A same-day touch-up can restore shape and comfort with minimal preparation, though color matching can be more challenging if the original bonding has aged.

Bridges add another layer of complexity. If a bridge feels loose at one end, the supporting teeth need careful evaluation. A bridge can loosen because the cement failed, because one abutment tooth developed decay, or because the fit has been altered by bite forces. Patients sometimes assume a loose bridge just needs glue. In reality, forcing it back into place can trap debris or damage a support tooth.

What to do before you reach the office

The period between the accident and the appointment matters. Good first aid will not replace treatment, but it can reduce pain and improve the chance of saving the restoration.

- Save any broken piece, rinse it gently, and place it in a clean container.
- Rinse your mouth with lukewarm water to clear debris.
- If there is swelling, use a cold compress on the outside of the face for short intervals.
- Cover a sharp edge with orthodontic wax or sugar-free gum if it is cutting your cheek or tongue.
- Avoid chewing on that side, especially hard, crunchy, sticky, or very hot and cold foods.

One practical point is worth stressing: do not use super glue or household adhesive. Dentists see this more often than you might think, especially before weddings, photographs, or travel. These products are not designed for oral tissues, can irritate the gums, and make professional repair harder. Temporary dental cement from a pharmacy is sometimes reasonable for a crown that has come off, but even then it should be used cautiously and only if the fit is obvious and there is no significant pain. If the crown does not seat fully, stop. Forcing it can crack the tooth or lock it in the wrong position.

What happens at an emergency dentist appointment

A well-run emergency visit is part diagnosis, part damage control, part planning. Patients often want a single answer the moment they sit down, but the safest treatment comes after a few key questions. How did it break? Was there trauma? Is there pain to cold, pressure, or touch? Did the restoration feel loose beforehand? Has the bite changed? These details help distinguish a simple restoration failure from a deeper tooth problem.

The exam usually starts with visual inspection and gentle probing around the affected tooth. If the area is sensitive, the dentist may dry it selectively rather than blast air directly, which can be miserable on exposed dentin. Bite evaluation is important. Many veneer and bonding fractures are not just bad luck. They happen because the edge of the restoration has been carrying too much force, often during night grinding or edge-to-edge contact.

Radiographs are frequently part of the visit, especially when the restoration was large, the tooth is tender, or a crack is suspected. An X-ray will not show every crack, but it can reveal recurrent decay, changes around the root, and whether the underlying tooth has enough structure left for a predictable repair.

From there, treatment falls into one of three categories. The first is definitive same-day repair, such as smoothing a chip, replacing a lost filling, or rebonding where conditions are ideal. The second is temporary stabilization, which might include a sedative filling, a provisional crown, or covering exposed dentin until the final restoration is fabricated. The third is escalation, when the emergency uncovers infection, nerve involvement, or a crack that changes the plan entirely.

The difference between a quick fix and a lasting fix

This is where experience matters. A patient in pain often wants the fastest option, and that is understandable. But speed alone can be expensive if it leads to repeat failure. For example, adding bonding to a chipped veneer edge may look acceptable for a while, but if the chip happened because the bite is too heavy on that edge, the repair may not last a month. Likewise, recementing a crown without checking why it loosened can be little more than a pause button.

Dentists make these calls by balancing biology, mechanics, and patient priorities. A college student leaving town the next morning may need a stable temporary solution with a plan for definitive care later. A patient with a public-facing job may place a premium on immediate esthetics, even if that means returning for refinement. A patient with severe grinding may need both repair and prevention at the same time, which could include a night guard once the tooth is restored.

One common example is the front veneer that chips repeatedly in the same place. If the emergency visit only restores the chip each time, the pattern continues. The real solution may involve adjusting bite contacts, changing the material, or redesigning the shape so the edge is not acting like a stress point. The same principle applies to crowns on heavily loaded back teeth. When a crown fractures twice, the conversation should expand beyond replacement to include occlusion, clenching habits, and whether the tooth itself has become structurally compromised.

Pain, sensitivity, and what they can tell you

The type of discomfort often provides useful clues. A sharp jolt to cold that fades quickly usually suggests exposed dentin. It is unpleasant, but often manageable with prompt coverage. Pain when biting down can point to a loose restoration, a high spot in the bite, or a crack in the tooth. Lingering pain to heat or cold raises more concern about pulpal inflammation. Throbbing pain, swelling, or tenderness to tapping can signal infection or a tooth that may need root canal treatment before a new restoration can succeed.

Patients sometimes feel embarrassed when a restoration breaks during ordinary eating. They say they were "just having a sandwich" or "only chewing pasta." That history can actually be significant. Strong, healthy restorations usually do not fail under light force unless something has changed, such as hidden decay, cement breakdown, a crack, or chronic fatigue from grinding. A dramatic fracture during a hard bite is easier to explain. A quiet failure during a soft meal often deserves a closer look.

Costs, insurance, and the value of timing

Emergency dental care can feel financially unpredictable, especially when the problem started with previous dental work. The cost depends on whether the solution is a simple repair, a new restoration, or a larger intervention such as root canal treatment. There is also the question of whether the original restoration can be reused. Recementing an intact crown is usually far less expensive than replacing it. Repairing a chipped bonding edge is usually more affordable than remaking a porcelain veneer.

Insurance coverage varies widely. Some plans treat emergency exams and X-rays separately from restorative treatment. Others cover a portion of crown or filling replacement based on frequency limits, not urgency. Veneers are often excluded when placed for cosmetic reasons, though a broken veneer can still require urgent clinical care. It helps when the dental office explains, in plain language, which part of the fee covers diagnosis, which part covers stabilization, and which part is tied to final treatment. Clear communication prevents a stressful appointment from turning into a billing dispute.

Timing affects cost in a practical way. A loose crown that is re-cemented promptly may avoid needing a remake. A lost filling replaced early may prevent a deeper cavity or fracture. Delay does not always make things

catastrophic, but it often narrows the least invasive options.

Situations that need especially careful judgment

Some cases sit in a gray zone where the right answer is not obvious in the first ten minutes. One is the veneer or crown on a tooth that has already had multiple restorations. Every time material is added or removed, the remaining tooth changes. At some point, the most conservative-looking repair may stop being the most conservative choice because it sets the tooth up for another failure.

Another tricky situation is trauma. If a veneer chips because of a fall, sports injury, or impact, the restoration may be the smallest part of the problem. Teeth can be bruised, roots can crack, and nerves can lose vitality days or weeks after the event. A tooth that tests normal at the emergency visit may need follow-up. This is why dentists often schedule review appointments after trauma, even when the immediate repair looks straightforward.

Patients with grinding habits create their own category. Nighttime clenching can shear porcelain, loosen crowns, and pop off bonding. If the emergency care restores the visible damage but ignores the habit, the repair lives on borrowed time. In those cases, long-term success may depend as much on bite protection as on the material used.

There is also the esthetic edge case, which matters more than people sometimes admit. A tiny chip on a front tooth can be clinically minor and personally major. For someone who speaks publicly, works in sales, or is getting married in a week, appearance is not vanity. It is part of daily function. Good emergency care respects that without promising more than is realistic in one visit.

How dentists decide between repair and replacement

The decision often comes down to four factors: how much of the restoration is damaged, how much healthy tooth remains, whether the margins are sound, and what caused the failure. If the damage is localized and the rest of the restoration is performing well, repair can be a sensible choice. If the margins are leaking, decay is present, or the fracture pattern shows broader weakness, replacement is usually wiser.

Here is the way that discussion often sounds in a real operatory.

- If the restoration failed but the tooth is healthy, a direct repair may be efficient and conservative.
- If the tooth underneath is compromised, a larger remake may actually preserve more structure over time.
- If the bite caused the damage, adjusting forces is part of the treatment, not an optional extra.
- If esthetics are critical, temporary repairs may need to be framed honestly as temporary.
- If symptoms suggest nerve involvement, the restoration decision may have to wait until the tooth is stabilized biologically.

That balancing act is what separates emergency dental care from a patch job. The best emergency dentist is not the one who simply gets something back on the tooth fastest. It is the one who recognizes when a quick repair will hold, when it will not, and how to keep the patient comfortable while the right treatment is arranged.

Aftercare once the immediate problem is handled

After the appointment, what happens over the next few days can influence the result. If the repair was temporary, softer foods and careful chewing are usually wise. If anesthesia was used, patients need the usual reminder not to chew while numb, especially if lips or cheeks are still heavy. A repaired front edge should not become a tool for

opening packets, biting nails, or tearing tape. It sounds obvious, but many anterior restorations fail from exactly those habits.

Sensitivity after treatment is not unusual, particularly when a previously sealed surface has been exposed. Mild temperature sensitivity that settles is common. Worsening pain, swelling, a feeling that the bite is too high, or a repaired piece that feels mobile again should prompt a return call. Patients often hesitate because they do not want to "bother the office." In dentistry, a small post-op adjustment can prevent a much bigger setback.

If the original cause appears to be grinding, this is the moment to act on it. A night guard is not glamorous, but it is far cheaper and less frustrating than remaking restorations every year or two. If the cause was decay at a margin, home care and recall intervals need honest review. Broken dental work is sometimes just bad luck. Sometimes it is a sign that the whole environment in the mouth needs attention.

Preventing the next emergency

Prevention is not only about brushing and flossing, though both matter. It is also about respecting the limits of restorations. Veneers are not meant for cracking ice. Temporary crowns are not permanent. Bonding on the edge of a front tooth may need occasional maintenance. Large fillings in back teeth are often transition restorations, doing useful work until the tooth needs cuspal coverage.

Regular exams help because failures are often detectable before they become emergencies. A crown margin that is starting to open, a small chip with wear marks, or a patient reporting morning jaw tension can all be early warnings. When those signs are addressed early, treatment tends to be smaller, simpler, and cheaper.

For patients, the best practical rule is this: if dental work breaks, loosens, falls out, or suddenly feels different, do not wait to see whether it settles on its own. Teeth do not heal the way skin does. Restorations do not tighten back up with time. Fast assessment often creates better options, even when the final repair is not done the same day.

A broken veneer or damaged crown can feel dramatic, especially when it affects your smile or interrupts your routine. Most of these situations are manageable with the right emergency dentist, a prompt exam, and a plan grounded in what the tooth actually needs. The immediate fix matters, but the long-term success depends on understanding why it happened and choosing a repair that respects both appearance and function.

Smyle Dental Bakersfield
2016 E St, Bakersfield, CA 93301, United States

+16614939040

FAQ About Emergency Dentist

What counts as a dental emergency?

Severe tooth pain, facial swelling, uncontrolled bleeding, a knocked-out or displaced tooth, and significant dental trauma may need prompt assessment. Trouble breathing or rapidly increasing swelling requires urgent medical help.

What should I do if a permanent tooth is knocked out?

Handle the tooth by the crown rather than the root, keep it moist, and contact a dentist immediately. Fast treatment can improve the chance of saving the tooth.

Can an emergency dentist treat severe tooth pain the same day?

Same-day care may be available depending on the cause and schedule. The dentist will examine the area, may take digital X-rays, and recommend treatment based on the diagnosis.

Should I go to the emergency room for dental swelling?

Seek urgent medical care for trouble breathing, difficulty swallowing, rapidly spreading facial swelling, or other severe symptoms. A dentist can assess the underlying dental cause and provide appropriate follow-up care.